

Short- and Long-term Effect of Nifedipine on the Visual Field in Patients with Presumed Vasospasm

P. Gasser¹ and J. Flammer²

¹Department of Internal Medicine, St Claraspital, Basel, Switzerland; ²Department of Ophthalmology, University of Basel, Basel, Switzerland

It is assumed that the ocular circulation may be involved in the vasospastic syndrome and patients with vasospasm have visual field defects that are neither ophthalmologically nor neurologically explainable. A retrospective study showed that 20 mg sustained-release nifedipine treatment given orally may be helpful in these cases. There was a marked short-term effect in cases with proven peripheral vasospasms but not in similar cases without such vasospasms. The study also showed that the effect could last for up to 12 months when 20 mg nifedipine was given twice daily but the long-term effect was slightly less than the short-term effect. A number of patients had to discontinue nifedipine treatment due to side-effects.

KEY WORDS: Nifedipine; vasospasm; nailfold videomicroscopy; cold provocation test; visual field.

INTRODUCTION

The aim of glaucoma treatment is to preserve the visual functions and in the case of high tension glaucoma this is mainly achieved by reducing the intra-ocular pressure. Although it is still debatable how much such a reduction influences

the progress of the disease, the majority of the clinicians are convinced that a reduction in the pressure is essential. This approach, however, may not be of use in patients with normal tension glaucoma. Even if in these patients the intra-ocular pressure is involved in the pathogenesis of the glaucomatous damage, a further reduction in the pressure is difficult to achieve and it is not yet clear how much a further reduction of the intra-ocular pressure would prevent further progression of the glaucomatous damage.

There is increasing evidence that other

Received for publication 9 May 1990; accepted 16 May 1990.

Address for correspondence: Paul Gasser, MD, Department of Internal Medicine, St Claraspital, Kleinfriedenstrasse 30, CH-4016 Basel, Switzerland.

pathogenetic mechanisms may also be involved in glaucoma and the following factors have been considered: sudden blood loss;¹ systemic orthostatic hypotension;² increased blood viscosity;³ migraine;⁴ and vasospastic disorders.⁵ The question therefore arises as to whether or not the progress of the disease can be affected by influencing these additional risk factors. If such a treatment were of help, it could be combined with treatment to lower the intra-ocular pressure or, in some cases, it could even replace it.

It has been observed that some patients with unexplained visual field defects had peripheral vasospasms;^{6,7} therefore, a systematic search was made among ophthalmic patients for peripheral vasospasms. A heterogeneous group of patients with peripheral vasospasms was identified who also had visual field defects and more or less normal visual acuity. In this group, there was no increase in the number of vasospasms in patients with unexplained decreased visual acuity but there was an increase in about 50% of those with unexplained visual field defects. In those patients that had a combination of visual field defects and vasospasms, the optic nerve head was found to be normal, slightly pale or excavated but in the majority of young patients the optic nerve head appeared normal. This led to the assumption that vasospasms in some patients may be able to provoke visual field defects without any detectable morphological changes and, in some cases, the optic nerve head might change resulting in 'normal tension glaucoma'.⁸ Phelps and Corbett⁴ first established a relationship between migraine and glaucoma, and Drance *et al.*⁹ demonstrated that peripheral vasospasms were more common in glaucoma patients than in 'normal' patients.

Previous studies have shown that when

Adalat retard® is a registered tradename of Bayer AG, Switzerland.

vasospastic patients were treated with the calcium channel blocker nifedipine a large improvement in the visual field was reported in some cases.¹⁰ This reversibility of the visual field defects was much more pronounced in young patients who still had a normal-looking optic nerve head than in older patients with optic nerve head cupping (the so-called normal tension glaucoma). Kitazawa *et al.*¹¹ confirmed, with the help of a control study, that nifedipine had a statistically significant beneficial effect even in normal tension glaucoma and he showed that the effect of nifedipine on the visual field was greater in cases with peripheral vasospastic disorders.

In view of these results it was thought that it would be worthwhile reviewing some of the clinical observations of the nifedipine treatment, which has been used since 1984, and an uncontrolled retrospective study was carried out on the influence of sustained-release nifedipine (Adalat retard®) on the visual fields in cases of proven peripheral and presumed ocular vasospasms.

PATIENTS AND METHODS

Patients

The retrospective study included patients with disturbed visual fields but without detectable ocular or neurological diseases, most patients complaining of fluctuating visual function. In some patients, the optic nerve head was slightly pale or slightly pathologically excavated and the mean intra-ocular pressure was less than 21 mmHg, with peak pressures of less than 25 mmHg. Patients with systemic diseases, such as multiple sclerosis, systemic hypertension, diabetes mellitus and cardiovascular diseases were identified by a neurologist and physician, and were excluded.

Treatment

All 62 patients received a single dose of 20 mg sustained-release nifedipine. In addition, a total of 24 patients with marked peripheral vasospasm underwent long-term

treatment with 20 mg sustained-release nifedipine given twice daily for 2, 6 or 12 months.

Measurement of visual field

The visual fields were measured 60 min after acute and after long-term nifedipine treatment using the G1 programme on the Octopus automated perimeter,¹² with both phases being tested; in order to avoid possible learning effects first examinations were not included in this analysis. For each patient one eye was selected randomly and the analysis was based on the mean defect.¹³ Only patients with a mean defect greater than 2 dB for at least two independent visual field tests were included.

Measurement of digital vasospasm

Nailfold videomicroscopy was performed in the fingers of seated patients using an intravital microscope according to the method of Mahler *et al.*¹⁴ The images obtained by means of a sensitive TV camera were projected on a TV monitor.

In the cooling provocation test, rapidly decompressed carbon dioxide was repeatedly directed to the nailfold area for 60 s and microscopy of the nailfold capillaries was carried out under normal conditions (baseline) and after local cooling of the finger. A blood flow stop of 14 s or more was indicative of peripheral vasospasm whereas a stop of less than 14 s was considered normal.

Statistical analysis

Data were analysed using Student's *t*-test.

RESULTS

The study included a total of 62 patients with reproducible but unexplained visual field defects; 48 patients had significant peripheral vasospasms in the capillaroscopic cooling test (group A) and the remaining 14 did not (control group B). Ages of patients in group A ranged from 16 to 82 years (mean \pm SD 48 ± 25 years) and in

group B from 22 to 71 years (mean \pm SD 40 ± 17 years).

The mean defect before treatment was 10.8 ± 5.7 dB for patients in group A (with digital vasospasm) and 12.4 ± 9.2 dB for those in group B (without digital vasospasm), and 60 min after nifedipine treatment it was 8.9 ± 5.4 dB for group A and 11.7 ± 9.2 dB for group B. The improvement in mean defect of 1.9 ± 2.8 dB for patients in group A was statistically significant ($P = 0.0001$) and the effect of the treatment was significantly larger for group A than for group B ($P = 0.017$) (Fig. 1).

The improvement after treatment with 20 mg nifedipine twice daily for 2 months was 4.96 ± 4.69 dB ($P = 0.020$), 4.28 ± 3.84 dB ($P = 0.017$) after 6 months and 3.31 ± 5.08 dB ($P = 0.09$) after 12 months (Fig. 2).

There was a slight, but not statistically significant reduction in blood pressure in the sitting position following short-term nifedipine treatment from $126 \pm 11/84 \pm 11$ mmHg to $121 \pm 12/81 \pm 12$ mmHg but the brachial blood pressure was not affected by long-term nifedipine treatment, even in cases tending to hypotension.

Side-effects, such as headaches (three patients), flushing (two patients), ankle oedema (one patient) and palpitations (three patients), were reported. The headache and palpitations mostly abated appreciably or completely disappeared in the course of the first month's treatment but ankle oedema tended to persist. Long-term nifedipine treatment was withdrawn in seven patients because of persistent oedema and headache, and these patients were not evaluated.

DISCUSSION

A vasospastic disorder may not only involve finger or coronary arteries but also vessels in the visual system.⁶ Such ocular vasospasms may involve the ciliary or choroidal circulation¹⁵ and may, therefore, influence the circulation in the optic nerve head, leading to glaucoma-like visual field

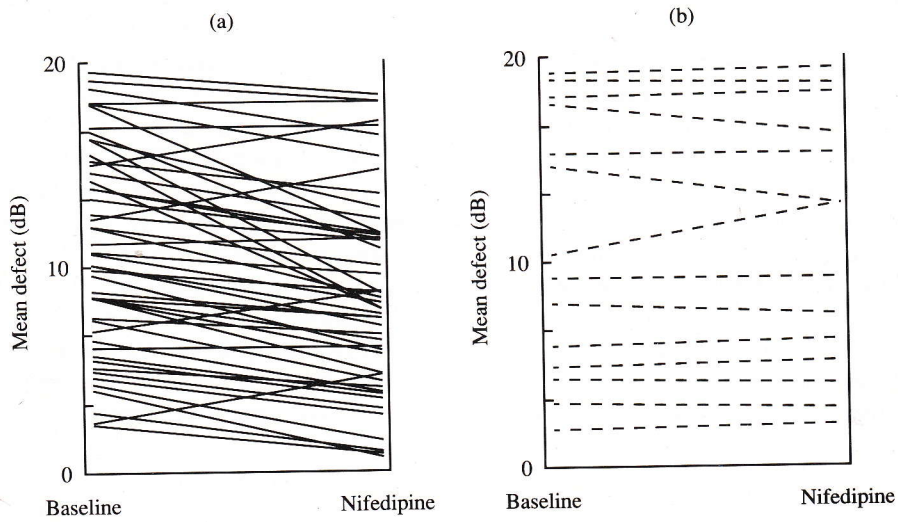


Fig. 1. Mean defect of the visual field test at baseline and 60 min after intake of 20 mg sustained-release nifedipine in (a) patients with digital vasospasm and (b) patients without digital vasospasm.

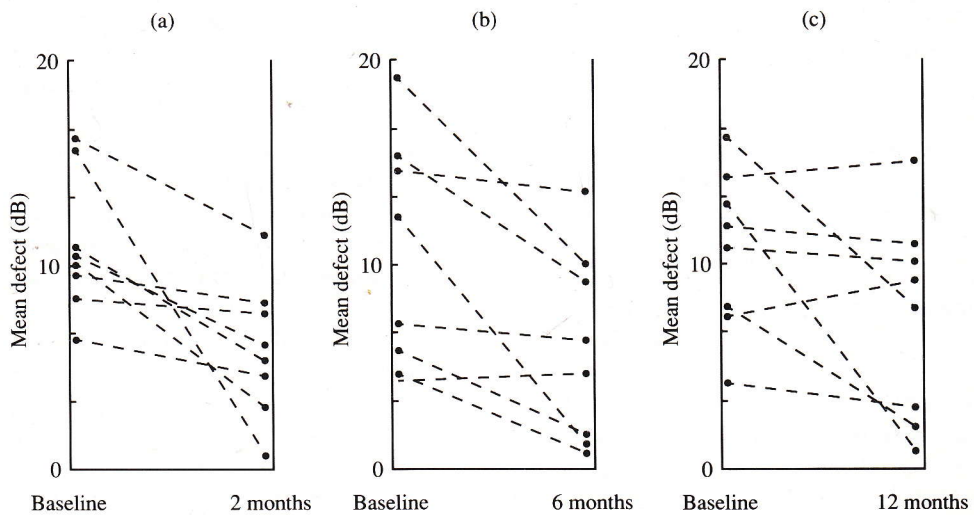


Fig. 2. Mean defect of the visual field test at baseline and after (a) 2 months', (b) 6 months' and (c) 12 months' treatment with 20 mg sustained-release nifedipine tablets twice daily.

defects. Increased prevalence of peripheral vasospasms in patients with glaucoma has been demonstrated⁹ and provocation tests have indicated that there is a relationship between peripheral and ocular vasospasms.⁷

Treatment of vasospasms is difficult due to the fact that the pathogenetic mechanism involved is not fully understood. One method of treatment has involved the use of calcium channel blockers, which are known to have some beneficial effect at least for peripheral vasospasms, and preliminary observations have indicated that nifedipine might also be helpful for treatment of ocular vasospasms.¹⁰ These results have been confirmed by Kitazawa *et al.*¹¹ with the help of a control study and the results of the present retrospective study suggest that nifedipine does have an influence on the visual fields and that this effect is markedly larger in patients with proven peripheral vasospasm compared with in those who had normal peripheral circulation, at least when considering short-term treatment. Little is known about the long-term effect of nifedipine on the visual field, although the results of the present study indicate that the observed short-term effect may last for months in some cases if the treatment is continued.

The improvements in the visual fields described in the present study were much larger than those observed by Kitazawa *et al.*¹¹ but this was most probably due to the fact that they included only cases with glaucoma, whereas in this study the population was more heterogeneous, including not only patients with cupped optic nerve heads but also cases with normal or slightly pale optic discs.

The present study showed that nifedipine was well tolerated in most cases, but following long-term treatment patients did experience subjective side-effects. It is therefore concluded, based on results published in the literature and on the present results, that further controlled

long-term studies should be performed.

ACKNOWLEDGEMENTS

This study was supported in part by the Swiss National Science Foundation, grant no. 32-9367.87. The authors thank Bayer AG, Switzerland, for generous supplies of nifedipine.

REFERENCES

1. Drance SM, Sweeny VP, Morgan RW, *et al*: Studies of factors involved in the production of low tension glaucoma. *Arch Ophthalmol* 1973; **89**: 457 - 465.
2. Demailly P, Cambien F, Plouin PF, *et al*: Do patients with low tension glaucoma have particular cardiovascular characteristics? *Ophthalmologica* 1984; **188**: 65 - 75.
3. Trope GE, Salinas RG, Glynn M: Blood viscosity in primary open-angle glaucoma. *Can J Ophthalmol* 1987; **22**: 202 - 204.
4. Phelps D, Corbett JJ: Migraine and low-tension glaucoma. A case-control study. *Invest Ophthalmol Vis Sci* 1985; **26**: 1105 - 1108.
5. Gasser P: Ocular vasospasm: a risk factor in the pathogenesis of low-tension glaucoma. *Int Ophthalmol* 1989; **13**: 281 - 290.
6. Gasser P, Flammer J: Influence of vasospasm on visual function. *Doc Ophthalmol* 1987; **66**: 3 - 18.
7. Guthauser U, Flammer J, Mahler F: The relationship between digital and ocular vasospasm. *Graefes Arch Clin Exp Ophthalmol* 1988; **226**: 224 - 226.
8. Flammer J, Guthauser U, Mahler F: Do ocular vasospasms help cause low tension glaucoma? *Doc Ophthalmol Proc Series*, 1987; pp 397 - 399.
9. Drance SM, Douglas MD, Wijsman K, *et al*: Response of blood flow to warm and cold in normal and low-tension glaucoma patients. *Am J Ophthalmol* 1988; **105**: 35 - 39.
10. Gasser P, Flammer J, Mahler F: Einsatz von Kalziumantagonisten bei der Behandlung okulärer Durchblutungsstörungen im Rahmen des vasospastischen Syndroms. *Schweiz Med Wochenschr* 1988; **118**: 201 - 202.
11. Kitazawa Y, Shirai H, Go FJ: The effect of Ca²⁺-antagonist on visual field in low-tension glaucoma. *Graefes Arch Clin Exp Ophthalmol* 1989; **227**: 408 - 412.
12. Flammer J, Jenni A, Keller B, *et al*: The Octopus glaucoma program G1. *Glaucoma* 1987; **9**: 67 - 92.
13. Flammer J: The concept of visual field indices. *Graefes Arch Clin Exp Ophthalmol* 1987; **224**: 389 - 392.

14. Mahler F, Saner H, Boss C, *et al*: Local cold exposure test for capillaroscopic examination of patients with Raynaud's syndrome. *Microvasc Res* 1987; **33**: 422 - 427.
15. Prünke C, Flammer J: Choroidal angiography

findings in patients with glaucoma-like visual field defects. In: *Perimetry Update 88/89* (Heiyl A, ed). Amsterdam: Kugler and Ghedini, 1989; pp 325 - 327.