

## Leber's Hereditary Optic Neuropathy, Normal Tension Glaucoma, and Flammer Syndrome: Long Term Follow-up of a Patient

### Lebersche hereditäre Optikusneuropathie, Normaldruckglaukom und Flammer-Syndrom – eine langzeitige Beobachtung eines Patienten

#### ABBREVIATIONS

FS	Flammer syndrome
LHON	Leber's hereditary optic neuropathy
NTG	normal tension glaucoma
ONCS	optic nerve compartment syndrome
ONH	optic nerve head
PVD	primary vascular dysregulation
RVP	retinal venous pressure

combined with Flammer syndrome (FS) [1–3], who developed a classical phenotype of a Leber's hereditary optic neuropathy (LHON) in one eye, subsequently chronic progressive normal tension glaucoma (NTG) in the other eye, and finally, optic nerve compartment syndrome (ONCS) [4] and a marked increase in the retinal venous pressure (RVP) [5] on both sides. This stimulated the discussion of whether these individual clinical and laboratory findings were an accidental concurrence, or whether they were dependent on each other.

history of a rapid unilateral drop in vision, beginning approximately 4 years previously. His visual acuity was 0.8 in the right eye and 0.2 in the left eye, and the intraocular pressure (IOP) was constantly below 17 mmHg. The visual field was normal on the right side, but had a relative central scotoma on the left side. The optic nerve head (ONH) was normal in the right eye, but pale and slightly cupped on the left side. An analysis of the mitochondrial DNA (mtDNA) revealed a G7444A mutation confirming the suspicion of LHON in the left eye.

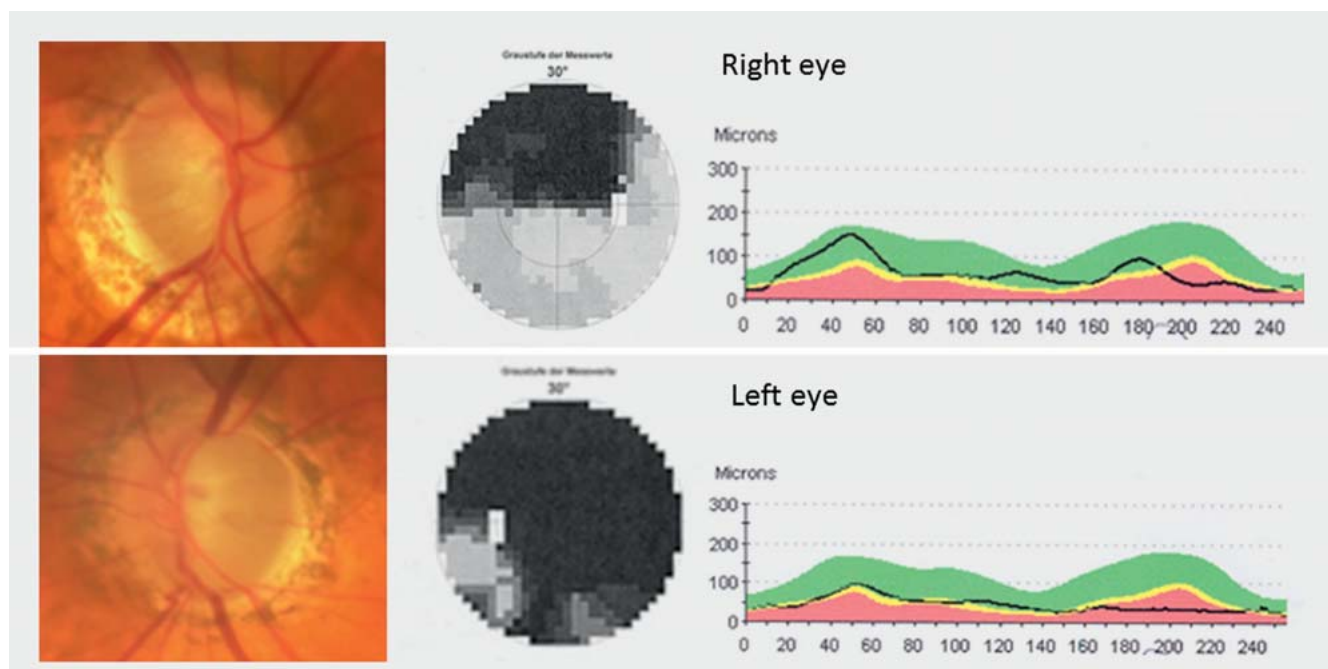
#### Background

In our clinic, we observed a patient with the risk constellation of a mitochondrial DNA mutation (G7444A-mutation) com-

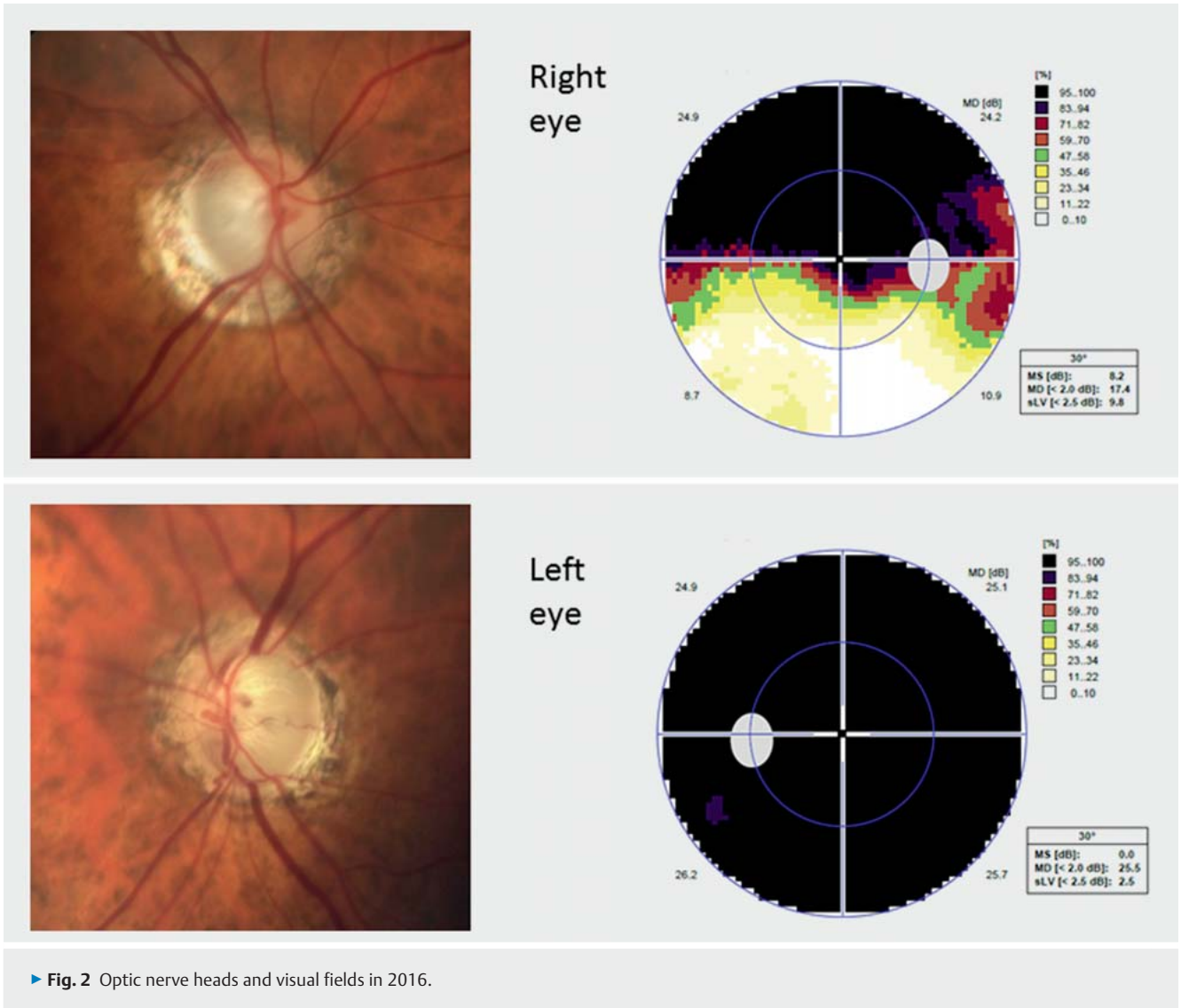
#### Case Presentation

In 1995, a 65-year-old man was referred for a second opinion to our clinic with a

In addition, the patient history was typical for FS [1], and confirmed by arterial hypotension, prolonged flow cessation after cold provocation in nailfold capillary mi-



► Fig. 1 Optic nerve heads, visual fields, and OCT RNFL thickness analysis in 2008.



crosscopy, and an elevated endothelin plasma level.

In order to mitigate the FS symptoms, combined therapy with magnesium, a low dose of Nifedipine, and ginkgo biloba was introduced, but stopped by the patient after one year.

Thirteen years later (2008), the patient was admitted again. This time for a slowly progressive scotoma in the right eye with corresponding ONH excavation (► **Fig. 1**), but a good visual acuity of 0.8. The IOP was less than 17 mmHg, and the OCT showed an inferotemporal nerve fiber bundle defect on the right side, while the left ONH was atrophic (► **Fig. 1**). In addition to the prior diagnosis of LHON in the

left eye, chronic progressive NTG of the right eye was diagnosed. Again, FS was confirmed.

Eight years later (2016), we had the chance to see this patient again. This time, his visual acuity had dropped to 0.1 in the right eye and remained at finger counting in the left eye. The IOP was 12 mmHg in the right eye and 13 mmHg in the left eye. Both optic discs were pale, with advanced eccentric excavation on the right side and a subtotal but not deep excavation on the left side, with corresponding visual field defects (► **Fig. 2**). The RVP was increased to 54 mmHg in the right eye and 50 mmHg in the left eye. The eye socket echography revealed moderate optic nerve compartment syndrome (ONCS) on

the right side and explicit ONCS on the left side [4,6]. The symptoms and signs of FS were still present, although they normally mitigate with age.

## Discussion

Here, we have described a case of unilateral LHON (mutation G7444A) combined with subsequent NTG in the fellow eye in the presence of FS.

LHON leads to an acute or subacute drop in vision with central visual field defects, starting in one eye and involving the other eye weeks or months later. In contrast to the course in our patient, vision loss occurred within three weeks or less in about

90% of Dutch patients [7]. In over 95% of the cases, the fellow eye becomes involved within one year [8]. The majority of the patients carry an mtDNA mutation; in addition to this, local and/or systemic factors obviously play a role as well [9].

At least 30 separate gene mutations are known to give rise to the clinical picture of LHON. Some mutations have high penetration (np 11778, np 3460, np 4160, np 15257), while others have only low penetration [10]. In this patient, the mutation was a G-to-A transposition at nucleotide pair (np) 7444 in the mtDNA. This mutation eliminates the terminal codon of the cytochrome-C oxidase, thereby reducing the complex IV activity, and has been reported to be statistically related to the disease [11]. Moreover, the same mutation has also been found in patients with aminoglycoside-induced hearing loss [12].

In contrast, NTG is a slowly progressive disease, but both LHON and NTG are consequences of mitochondrial dysfunction [13], in which oxidative stress plays a major role. If the mitochondria are weakened from the outset by an mtDNA mutation, major oxidative stress may lead to a relatively rapid decompensation. In contrast, NTG patients have mostly normal mtDNA; therefore, oxidative stress may take much longer to damage the mitochondria to the extent that the energy supply becomes insufficient. There are a number of potential causes of oxidative stress, such as smoking, which is known to be associated with LHON [14]. Our patient suffered from primary vascular dysregulation (PVD) [2], which is the main vascular component of FS [1]. In FS subjects, weakened autoregulation insufficiently compensates for the fluctuations in the IOP and blood pressure. This results in an instable ocular blood supply increasing oxidative stress in the mitochondria.

In contrast to NTG, the fast disease process of LHON leads to less tissue remodeling; therefore, after the acute phase, the ONH is mostly pale and only slightly excavated [15].

On the occasion of the last consultation (2016) for this patient, we conducted two additional examinations not available in

our clinic previously, namely: measurement of the RVP [5] and eye socket echography, searching for ONCS [6]. While the RVP is equal to or slightly higher than the IOP in healthy subjects, it is often increased in patients with ophthalmic and systemic diseases [5], such as NTG. This is particularly the case in the presence of a FS. Indeed, our patient had markedly increased RVP in both eyes.

In addition, the eye socket echography revealed the presence of the ONCS on both sides. ONCS [4] is a pathological condition in which the cerebrospinal fluid is partly or totally segregated between the subarachnoid space surrounding the optic nerve and the intracranial subarachnoid space. This leads to the extension of the optic nerve sheath diameter and an altered chemical composition of the cerebrospinal fluid. ONCS has often been demonstrated in patients with NTG [4], particularly in the presence of FS [6]. However, the pathogenesis of ONCS has not yet become totally clear.

## Conclusion

LHON and NTG have some aspects in common. Both lead to visual field defects and ONH atrophy. In LHON, the course of the disease is much faster, involving the central visual field earlier, and leads to less ONH excavation. Both diseases are essentially due to a mitochondrial dysfunction. While in NTG the mitochondrial damage is acquired over a longer period of time, the mitochondria in LHON patients have an additional inborn weakness explaining the more rapid decompensation. The different time courses of the two diseases also explain the morphological differences in the ONH atrophy. In addition, our patient also had FS, a condition in which the ocular oxygen supply is unstable, leading to increased oxidative damage of the mitochondria. We hypothesize that FS may have contributed to both the manifestation of LHON and the development of NTG, as well as the ONCS and the increased RVP.

## Conflict of Interest

None.

## The Authors

K. Konieczka<sup>1</sup>, J. Flammer<sup>1</sup>, J. Sternbuch<sup>2</sup>, T. Binggeli<sup>1</sup>, S. Fraenkl<sup>3</sup>

<sup>1</sup> Department of Ophthalmology, University of Basel, Basel, Switzerland (Chairman: Prof. Dr. Hendrik Scholl)

<sup>2</sup> Private Practice, Zurich, Switzerland

<sup>3</sup> Department of Ophthalmology, University of Bern, Bern, Switzerland (Chairman: Prof. Dr. Dr. Sebastian Wolf)

## References

- [1] Konieczka K, Ritch R, Traverso CE et al. Flammer syndrome. *EPMA J* 2014; 5: 11
- [2] Flammer J, Konieczka K, Flammer AJ. The primary vascular dysregulation syndrome: implications for eye diseases. *EPMA J* 2013; 4: 14
- [3] Flammer J, Konieczka K, Bruno RM et al. The eye and the heart. *Eur Heart J* 2013; 34: 1270–1278
- [4] Killer HE. Compartment syndromes of the optic nerve and open-angle glaucoma. *J Glaucoma* 2013; 22 (Suppl. 5): S19–S20
- [5] Flammer J, Konieczka K. Retinal venous pressure: the role of endothelin. *EPMA J* 2015; 6: 21
- [6] Konieczka K, Todorova MG, Bojinova RI et al. Unexpected effect of calcium channel blockers on the optic nerve compartment syndrome. *Klin Monatsbl Augenheilkd* 2016; 233: 387–390
- [7] Spruijt L, Kolbach DN, de Coo RF et al. Influence of mutation type on clinical expression of Leber hereditary optic neuropathy. *Am J Ophthalmol* 2006; 141: 676–682
- [8] Newman NJ. Hereditary optic neuropathies: from the mitochondria to the optic nerve. *Am J Ophthalmol* 2005; 140: 517–523
- [9] Yen MY, Wang AG, Wei YH. Leber's hereditary optic neuropathy: a multifactorial disease. *Prog Retin Eye Res* 2006; 25: 381–396
- [10] Eichhorn-Mulligan K, Cestari DM. The genetics of Leber hereditary optic neuropathy – prototype of an inherited optic neuropathy with mitochondrial dysfunction. *Semin Ophthalmol* 2008; 23: 27–37
- [11] Brown MD, Yang CC, Trounce I et al. A mitochondrial DNA variant, identified in Leber hereditary optic neuropathy patients, which extends the amino acid sequence of cytochrome C oxidase subunit I. *Am J Hum Genet* 1992; 51: 378–385

- [12] Jin L, Yang A, Zhu Y et al. Mitochondrial tRNA<sup>Ser</sup>(UCN) gene is the hot spot for mutations associated with aminoglycoside-induced and non-syndromic hearing loss. *Biochem Biophys Res Commun* 2007; 361: 133–139
- [13] Lopez Sanchez MI, Crowston JG, Mackey DA et al. Emerging mitochondrial therapeutic targets in optic neuropathies. *Pharmacol Ther* 2016; 165: 132–152
- [14] Tsao K, Aitken PA, Johns DR. Smoking as an aetiological factor in a pedigree with Leber's hereditary optic neuropathy. *Br J Ophthalmol* 1999; 83: 577–581
- [15] Mashima Y, Kimura I, Yamamoto Y et al. Optic disc excavation in the atrophic stage of Leber's hereditary optic neuropathy: comparison with normal tension glaucoma. *Graefes Arch Clin Exp Ophthalmol* 2003; 241: 75–80

---

### Bibliography

---

DOI <http://dx.doi.org/10.1055/s-0042-119564>  
Published online 31.1.2017 | *Klin Monatsbl Augenheilkd* 2017; 234: 584–587 © Georg Thieme Verlag KG Stuttgart · New York | ISSN 0023-2165

### Correspondence

---

**Katarzyna Konieczka, MD**  
University of Basel  
Department of Ophthalmology  
Mittlere Strasse 91  
CH-4031 Basel  
Switzerland  
Phone: + 41/61/2 65 88 03  
Fax: + 41/61/2 65 86 52  
[Katarzyna.Konieczka@usb.ch](mailto:Katarzyna.Konieczka@usb.ch)