

# Is Vascular Regulation in the Central Retinal Artery Altered in Persons With Vasospasm?

Doina Gherghel, MD; Selim Orgül, MD; Barbara Dubler; Patricia Lübeck, MD; Konstantin Gugleta, MD; Josef Flammer, MD

**Objective:** To assess the relation between ocular perfusion pressure and blood flow velocity in the central retinal artery in patients with acral vasospasm.

**Subjects and Methods:** Eighteen otherwise healthy subjects with acral vascular dysregulation, as demonstrated by nail-fold capillaroscopy, and 18 age- and sex-matched healthy volunteers without vasospasm were recruited. After subjects had rested for 20 minutes in a supine position, intraocular pressure and blood flow velocity in the central retinal artery were determined by applanation tonometry and color Doppler imaging, respectively. The peak systolic velocity, end-diastolic velocity, and resistivity index were assessed. Correlations between the mean ocular perfusion pressure ( $2/3 \times [2/3 \times \text{diastolic blood pressure} + 1/3 \times \text{systolic blood pressure}] - \text{intraocular pressure}$ ) and blood flow velocities in the central retinal artery were determined by the Pearson linear correlation factor. The

Student *t* test was used to evaluate differences between controls and subjects with vasospasm.

**Results:** The mean  $\pm$  SD ocular perfusion pressure was  $42.0 \pm 7.4$  mm Hg in the group with vasospasm and  $47.1 \pm 6.5$  mm Hg in the control group ( $P = .04$ ). In the subjects with vasospasm, the peak systolic and end-diastolic velocities and the resistivity index of the central retinal artery correlated significantly with the mean ocular perfusion pressure ( $R = 0.49$ ,  $P = .04$ ;  $R = 0.58$ ,  $P = .01$ ; and  $R = -0.67$ ,  $P = .002$ , respectively). Such correlations were not found in the control group.

**Conclusion:** An altered blood flow regulation is suggested in the ocular circulation of patients with acral vasospasm.

*Arch Ophthalmol.* 1999;117:1359-1362

**G**LAUCOMA IS a progressive optic neuropathy involving characteristic structural changes of the optic nerve and characteristic visual field defects.<sup>1</sup> An increased intraocular pressure (IOP) is the risk factor most often associated with glaucomatous optic neuropathy. Ample evidence<sup>2</sup> suggests, however, that an increased IOP cannot be the only pathogenic factor in glaucomatous optic neuropathy. Among other variables that might be involved in the pathogenesis of glaucoma, vascular risk factors are the most extensively studied.<sup>3</sup> In particular, a vascular dysregulation that leads to local vasospasm or impaired autoregulation has been advocated as a possible contributing factor in the cause of glaucoma.<sup>4-6</sup> Vasospasms are normally defined as inappropriate vasoconstrictions without recognizable anatomic causes. A vasospastic diathesis might be expressed not only by a local vasoconstriction but also by an inappropriate vasodilation.<sup>7</sup>

Such a dysregulation would be equivalent to a lack of autoregulation.

The pathogenesis of the vasospastic syndrome is not clear. Some evidence<sup>8</sup> suggests that the local hormone endothelin 1 plays an important role. The clinical picture depends on the location of the spasms.<sup>9,10</sup> Typical manifestations include variant angina, the Raynaud syndrome, migraine, and systemic hypotension.<sup>11</sup> The vascular crisis can be provoked by many factors such as emotions, exposure to nicotine, and exposure to cold. The most accurate method to verify vasospasms is the direct observation of capillaries in the nail-fold skin (capillaroscopy), viewed under indirect illumination after the skin has been made transparent by the application of a drop of oil.<sup>11</sup>

Vasospasms in the retinal vessels have been observed in patients with unstable primary angina and those with migraine.<sup>12</sup> How such dysregulative phenomena might lead to structural

From the University Eye Clinic, Basel, Switzerland.

## PATIENTS AND METHODS

Thirty-six healthy subjects were included in this study. After informed consent was obtained, subjects were screened for ocular and systemic diseases. A detailed medical and ophthalmic history was recorded, and all subjects completed an ophthalmologic examination. Subjects were not included if they had a history of ocular or systemic disease, a family history of glaucoma, a history of eye surgery, any long-term systemic or topical medication use, a best corrected visual acuity worse than 20/25, an IOP of 20 mm Hg or higher, or any pathological finding on ophthalmologic examination, including slitlamp biomicroscopy and funduscopy.

In the first step, 18 healthy subjects (16 women and 2 men) were recruited from volunteers—collaborators, students, and parents and friends of patients—who responded to a notice posted at the University Eye Clinic, Basel, Switzerland, of the opportunity to participate in a scientific research project. The subjects were encouraged to participate if they often had cold hands. Inclusion criteria for this first group was the presence of digital vasospasm demonstrated by capillaroscopy. Of 38 subjects who volunteered, 14 were excluded initially—2 who had a family history of glaucoma, 10 who took some long-term medication, 1 who had amblyopia, and 1 who had an increased IOP. Of the remaining 24 volunteers, 5 were excluded because they did not have any digital vasospastic reaction during capillaroscopy, and 1 subject was excluded because of high systemic blood pressures during color Doppler imaging (CDI). In the second step, after 18 healthy subjects with a vasospastic diathesis had been identified, 18 age- and sex-matched controls were recruited, again through a notice posted at the University Eye Clinic. This time, only subjects who did not often have cold hands were encouraged to participate. The inclusion criterion for the second group was the absence of digital vasospasm, as assessed by capillaroscopy. Subjects were recruited until 18 controls matched by age and sex with the first group were identified and completed the study. During this phase, 8 subjects were excluded because of the long-term use of systemic medication, and 2 subjects were excluded because of a vasospastic reaction during capillaroscopy.

All the subjects underwent microscopic examination of their nail-fold capillaries, as described previously.<sup>16</sup> Blood flow velocity can be easily assessed by observing the flow of cellular elements in the capillaries that run parallel to the skin surface. For this purpose, a light microscope is coupled to a television monitor that is in turn coupled to a video recorder, allowing the observed blood flow to be videotaped for later analysis. During capillaroscopy, the nail-fold area is cooled to  $-15^{\circ}\text{C}$  for 60 seconds by rapidly decompressing carbon dioxide. The examination is performed in a room with a constant temperature of about  $23^{\circ}\text{C}$  (range,  $21^{\circ}\text{C}$ - $25^{\circ}\text{C}$ ). During cooling, the blood in the capillaries sometimes stops flowing. Digital vasospasm is defined as a closing of 1 or more visible capillaries, with a mean stoppage time of longer than 12 seconds.

All the subjects underwent assessment of the blood flow velocity of their central retinal artery (CRA) by CDI. Blood flow velocity in the CRA was measured by a color Doppler imaging device (Quantum 2000; Siemens Albis AG, Zürich, Switzerland) using a 7.5-MHz linear phase array transducer. Using a coupling gel, the transducer is applied gently to the closed eyelid, with care taken to avoid applying any pressure to the eye. During the examination, subjects are in the supine position, with the head tilted forward at about a  $30^{\circ}$  angle. The CRA is examined in the anterior part of the optic nerve shadow. In this vessel, the peak systolic velocity (PSV), the end-diastolic velocity (EDV), and the resistivity index (RI)  $([\text{PSV} - \text{EDV}]/\text{PSV})$  were measured. The PSV is defined as the greatest velocity of blood flow during the systolic phase of the cardiac cycle. The EDV is defined as the velocity of blood flow at the end of the diastolic phase of the cardiac cycle.

The entire experimental procedure was standardized. After the presence or absence of a digital vasospastic reaction to local cooling was established, selected subjects rested for 20 minutes in a supine position. For all the subjects, the right eye was chosen arbitrarily as the experimental eye. Before CDI, the IOP was measured by an applanation tonometer (Perkins; Haag-Streit, Bern, Switzerland) after applying 1 drop of 0.4% benoxinate hydrochloride and staining the tear film with a strip of fluorescein sodium. Afterward, CDI measurements were obtained of the CRA. All CDI measurements were performed by the same experienced technician (B.D.). Throughout the experimental procedure, the systemic blood pressure and heart rate were recorded at 3-minute intervals by an automatic device (Profilomat; Disetronic, Burgdorf, Switzerland). This device measures the blood pressure automatically, using the same principle as the conventional mercury sphygmomanometer, with a cuff and a microphone. Subjects with relevant variations in blood pressure during the examinations were excluded.

The blood pressure readings for the systolic blood pressure (SBP) and the diastolic blood pressure (DBP), obtained just before CDI, were used to calculate the mean arterial blood pressure (MABP)  $(2/3 \times \text{DBP} + 1/3 \times \text{SBP})$ . The ophthalmic artery pressure (OAP) was calculated as two-third times the MABP. The mean ocular perfusion pressure (MOPP) was calculated as the OAP minus the IOP.

The correlation between the MOPP and blood flow velocities in the CRA was calculated by the Pearson linear correlation factor. To evaluate differences in regressions between subjects with vasospasm and controls, the interaction by the covariate MOPP (parallelism of regression lines) was computed using an analysis of covariance. Differences in hemodynamic measurements such as the SBP, DBP, MABP, OAP, and MOPP, as well as differences in the IOP between the group of subjects with vasospasm and the control group, were assessed by the Student *t* test for unpaired variables. Differences were considered statistically significant at  $P < .05$ .

ischemic lesions is not well understood. Indeed, most patients with a vasospastic diathesis do not have any disease. Vascular dysregulation, however, has been advocated to represent a possible risk factor in various ocular conditions, including glaucoma,<sup>2</sup> retinal venous occlusion,<sup>13</sup> acute ischemic optic neuropathy,<sup>14</sup> and

central serous chorioretinopathy.<sup>15</sup> Therefore, an assessment of blood flow regulatory mechanisms in the ocular circulation of subjects with vasospasm is warranted. This study was done to evaluate the relation between retinal blood flow velocity measurements and ocular perfusion pressure.

**Table 1. Hemodynamic Measurements and Intraocular Pressure in the Study Groups\***

Pressures, mm Hg	Subjects With Vasospasm (n = 18)	Control Group (n = 18)	P
Blood			
Systolic	115.4 ± 18.2	123.5 ± 14.1	.15
Diastolic	67.0 ± 10.7	73.6 ± 9.6	.06
Mean arterial	83.1 ± 12.2	90.2 ± 10.5	.07
Ophthalmic artery	55.4 ± 8.1	60.2 ± 7.0	.07
Mean ocular perfusion	42.0 ± 7.4	47.1 ± 6.5	.04
Intraocular	13.4 ± 2.2	13.1 ± 3.0	.69

\*Values are given as mean ± SD.

**Table 2. Blood Flow Measurements in the Right Central Retinal Artery in Study Groups\***

Blood Flow	Subjects With Vasospasm (n = 18)	Control Group (n = 18)	P
Peak systolic velocity, cm/s	9.2 ± 2.0	10.3 ± 1.1	.05
End-diastolic velocity, cm/s	2.2 ± 0.6	2.3 ± 0.5	.08
Resistivity index†	0.7 ± 0.1	0.7 ± 0.1	.73

\*Values are given as mean ± SD.

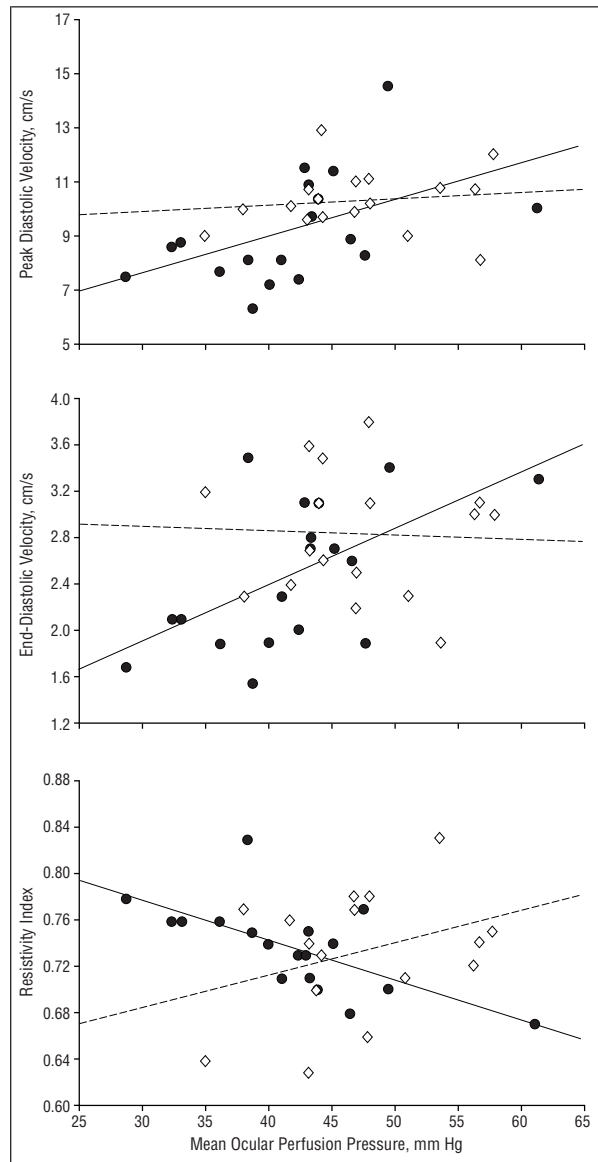
†Calculated as the peak systolic velocity minus the end-diastolic velocity divided by the peak systolic velocity.

## RESULTS

The mean ± SD age of the 18 subjects with vasospasm was 35 ± 11 years and of the 18 control subjects was 36 ± 10 years; each group was composed of 16 women and 2 men. Hemodynamic measurements have been outlined in **Table 1**. These measurements were comparable between the 2 experimental groups, except for the MOPP, which was significantly lower in subjects with vasospasm ( $P = .04$ ). The mean ± SD blood flow standstill time during cooling in capillaroscopy was 58.5 ± 24.9 seconds in the group with vasospasm. The CDI measurements of the CRA in the right eye of the group with vasospasm and the control group are shown in **Table 2**. These measurements were statistically comparable between the subjects with vasospasm and the control group. In the group with vasospasm, the MOPP correlated statistically with all 3 CDI measurements in the CRA (**Figure**). The correlation factors for the PSV, EDV, and RI were 0.5 ( $P = .04$ ), 0.6 ( $P = .01$ ), and -0.7 ( $P = .002$ ), respectively. Such correlations were not found in the control group ( $P$  values ranging from .19-.84). The difference between subjects with vasospasm and controls in the correlation between the MOPP and CDI measurements (divergence of the regression lines) was significant for the RI ( $F = 8.68$ ,  $P = .006$ ), borderline significant for the EDV ( $F = 3.77$ ,  $P = .06$ ), but not significant for the PSV ( $F = 2.08$ ,  $P = .16$ ) in a covariance analysis model.

## COMMENT

Blood flow autoregulation has repeatedly been demonstrated in the retinal circulation.<sup>17-23</sup> In the present study, however,



Mean ocular perfusion pressures (MOPPs) significantly affected blood flow in the central retinal artery of subjects with vasospasm (solid circles and solid line) but not in healthy controls (open diamonds and dotted line). The peak systolic velocity was positively correlated with the MOPP in subjects with vasospasm ( $R = 0.49$ ,  $P = .04$ ) but not in controls ( $R = 0.12$ ,  $P = .64$ ) (A); the end-diastolic velocity was positively correlated with the MOPP in subjects with vasospasm ( $R = 0.58$ ,  $P = .01$ ) but not in controls ( $R = -0.05$ ,  $P = .84$ ) (B); and the resistivity index was negatively correlated with the MOPP in subjects with vasospasm ( $R = -0.67$ ,  $P = .002$ ) but not in controls ( $R = 0.33$ ,  $P = .19$ ) (C).

the PSV and the EDV were positively correlated with the MOPP in subjects with vasospasm, suggesting that ocular blood flow might also decrease with decreasing perfusion pressure. A possible explanation for such a correlation is that vasodilation accounts for decreased blood flow velocities, but blood flow is preserved. This was not observed in the control group, however, suggesting that, if blood flow autoregulation is present in the retinal circulation of persons with vasospasm, the regulating mechanisms are different from those governing vascular tone in those without vasospasm. The observed increase in the RI in persons

with vasospasm with lower ocular perfusion pressure, however, suggests an altered autoregulation. The RI is a factor related to blood flow resistance in the vascular system downstream to the measurement point.<sup>24-26</sup> The RI was negatively correlated with the MOPP in subjects with vasospasm. In an autoregulated vascular bed, blood flow resistance is expected to decrease with decreasing perfusion pressure. The correlation between the RI and the MOPP would, however, depend on comparable metabolic needs in the retinal tissue of the subjects. Consequently, only a positive correlation, if any, between the RI and the MOPP is expected to occur in an autoregulated vascular bed such as the retinal circulation. Consequently, the negative correlation between the RI and the MOPP in subjects with vasospasm, which was statistically different from that observed in the control group, suggests a paradoxical peripheral vasoconstriction with decreasing perfusion pressure. This observation is in accordance with earlier findings,<sup>27</sup> suggesting an increased acral vasospasm with larger drops in the systemic blood pressure and an increased peripheral responsiveness to endothelin with decreasing systemic blood pressures in patients with vasospasm.<sup>28</sup> Subjects with vascular dysregulation seem to respond with a paradoxical peripheral vasoconstriction.

The present study demonstrated a decreased MOPP in otherwise healthy subjects with vasospasm. Besides a lower MOPP, variables such as the SBP, DBP, MABP, OAP, PSV, and EDV, although not statistically different in the present study, might also be lower in otherwise healthy subjects with vasospasm. This would have confirmed earlier observations of lower systemic blood pressures in subjects with vasospasm.<sup>29</sup> We could demonstrate only borderline-significant differences in the DBP, MABP, OAP (Table 1), PSV, and EDV (Table 2). The relatively small sample size might have hampered our current analysis. Nevertheless, these borderline differences suggest that other aspects may differentiate subjects with vasospasm from age- and sex-matched controls.

To the best of our knowledge, the findings of the present study demonstrate for the first time that blood flow alterations occur in the retinal circulation of subjects with vasospasm. Whether similar alterations exist in other ocular vessels, such as those feeding the anterior optic nerve or the choroid, is not known. Furthermore, vasospasms have been suggested to represent a risk factor for ophthalmic diseases such as glaucoma,<sup>2</sup> anterior ischemic optic neuropathy,<sup>14</sup> venous thrombosis in young persons,<sup>13</sup> or central serous chorioretinopathy.<sup>15</sup> Consequently, whether subjects afflicted by such diseases present similar alterations in their ocular circulation would be of utmost interest.

## CONCLUSIONS

A decreased MOPP was demonstrated in otherwise healthy subjects with vasospasm. In addition, an altered vascular regulation was seen in the retinal circulation of such subjects. Such alterations might render the eye susceptible to variations in the IOP or systemic blood pressures.

Accepted for publication June 14, 1999.

Reprints: Selim Orgül, MD, University Eye Clinic, Mittlere Strasse 96, 4012 Basel, Switzerland (e-mail: orguel@ubaclu.unibas.ch).

1. Van Buskirk EM, Cioffi GA. Glaucomatous optic neuropathy. *Am J Ophthalmol*. 1992;113:447-452.
2. Flammer J, Orgül S. Optic nerve blood-flow abnormalities in glaucoma. *Prog Retin Eye Res*. 1998;17:267-289.
3. Drance SM, Sweeney VP, Morgan RW, Feldman F. Studies of factors involved in the production of low-tension glaucoma. *Arch Ophthalmol*. 1973;89:457-465.
4. Pillunat LE, Stodtmeister R, Wilmanns I. Pressure compliance of the optic nerve head in low tension glaucoma. *Br J Ophthalmol*. 1987;71:181-187.
5. Flammer J. Psychophysics in glaucoma: a modified concept of the disease. In: Greve EL, Leydhecker W, Raitta C, eds. *Proceedings of the European Glaucoma Society, Second European Glaucoma Symposium*. Dordrecht, the Netherlands: Dr W Junk Publishers; 1985:11-17.
6. Gasser P, Flammer J, Guthauser U, Niesel P, Mahler F, Linder HR. Bedeutung des vasospastischen syndroms in der augenheilkunde. *Klin Monatsbl Augenheilkd*. 1986;188:398-399.
7. Flammer J. To what extent are vascular factors involved in the pathogenesis of glaucoma? In: Kaiser HJ, Flammer J, Hendrickson P, eds. *Ocular Blood Flow: New Insights Into the Pathogenesis of Ocular Diseases*. Basel, Switzerland: S Karger AG; 1996:12-39.
8. Lüscher TF. Endothelin: key to coronary vasospasm? *Circulation*. 1991;83:701-703.
9. Miller D, Waters DD, Warnica W, Szlachcic J, Kreeft J, Thérout P. Is variant angina the coronary manifestation of a generalized vasospastic disorder? *N Engl J Med*. 1981;304:763-766.
10. Gasser P, Flammer J, Mahler F. Is the evidence of vasospasms in the eye the expression of a generalized vasospastic disorder? In: Straw A, Novo S, eds. *Advances in Vascular Pathology*. Amsterdam, the Netherlands: Elsevier Science Publishers BV; 1989:1215-1220.
11. Mahler F, Saner H, Würbel H, Flammer J. Local cooling test for clinical capillaroscopy in Raynaud's phenomenon, unstable angina, and vasospastic visual disorders. *Vasa*. 1989;18:201-204.
12. Baksi KB, Rateria N. Spasm of the retinal vessels in association with unstable primary angina [letter]. *Chest*. 1984;86:155.
13. Messerli J, Flammer J. Zentralvenenthrombosen bei jüngeren patienten [Central vein thrombosis in younger patients]. *Klin Monatsbl Augenheilkd*. 1996;208:303-305.
14. Kaiser HJ, Flammer J, Messerli J. Vasospasm: a risk factor for nonarteritic anterior ischemic optic neuropathy? *Neuroophthalmology*. 1996;16:5-10.
15. Prünke C, Flammer J. Choroidal capillary and venous congestion in central serous chorioretinopathy. *Am J Ophthalmol*. 1996;121:26-34.
16. Gasser P, Flammer J. Blood-cell velocity in the nailfold capillaries of patients with normal-tension and high-tension glaucoma. *Am J Ophthalmol*. 1991;111:585-588.
17. Sossi N, Anderson DR. Effect of elevated intraocular pressure on blood flow: occurrence in cat optic nerve head studied with iodoantipyrine I 125. *Arch Ophthalmol*. 1983;101:98-101.
18. Grunwald JE, Sinclair SH, Riva CE. Autoregulation of the retinal circulation in response to decrease of intraocular pressure below normal. *Invest Ophthalmol Vis Sci*. 1982;23:124-127.
19. Riva CE, Sinclair SH, Grunwald JE. Autoregulation of retinal circulation in response to decrease of perfusion pressure. *Invest Ophthalmol Vis Sci*. 1981;21(pt 1):34-38.
20. Bill A, Sperber GO. Aspects of oxygen and glucose consumption in the retina: effects of high intraocular pressure and light. *Graefes Arch Clin Exp Ophthalmol*. 1990;228:124-127.
21. Hayreh SS, Bill A, Sperber GO. Effects of high intraocular pressure on the glucose metabolism in the retina and optic nerve in old atherosclerotic monkeys. *Graefes Arch Clin Exp Ophthalmol*. 1994;232:745-752.
22. Chemtob S, Beharry K, Rex J, Chatterjee T, Varma DR, Chemtob S. Free radicals in retinal and choroidal blood flow autoregulation in the piglet: interaction with prostaglandins. *Invest Ophthalmol Vis Sci*. 1994;35:580-591.
23. Hardy P, Abran D, Li DY, Fernandez H, Varma DR, Aranda JV. Ibuprofen enhances retinal and choroidal blood flow autoregulation in newborn piglets. *Invest Ophthalmol Vis Sci*. 1991;32:1799-1807.
24. Erickson SJ, Hendrix LE, Massaro BM, et al. Color Doppler flow imaging of the normal and abnormal orbit. *Radiology*. 1989;173:511-516.
25. Lieb WE, Cohen SM, Merton DA, Shields JA, Mitchell DG, Goldberg BB. Color Doppler imaging of the eye and orbit: technique and normal vascular anatomy. *Arch Ophthalmol*. 1991;109:527-531.
26. Williamson TH, Harris A. Color Doppler ultrasound imaging of the eye and orbit. *Surv Ophthalmol*. 1996;40:255-267.
27. Orgül S, Kaiser HJ, Flammer J, Gasser P. Systemic blood pressure and capillary blood-cell velocity in glaucoma patients: a preliminary study. *Eur J Ophthalmol*. 1995;5:88-91.
28. Gass A, Flammer J, Linder L, Romerio SC, Gasser P, Haefeli WE. Inverse correlation between endothelin-1-induced peripheral microvascular vasoconstriction and blood pressure in glaucoma patients. *Graefes Arch Clin Exp Ophthalmol*. 1997;235:634-638.
29. Gasser P. Clinical syndromes with vasoconstrictor response. *Wien Klin Wochenschr*. 1991;103:217-221.